

Diagnosis and Treatment of 'Dusn' Diffuse Unilateral Subacute Neuroretinitis

Prof. Dr. Luis E. Abad¹, Cruz Ruiz Gali Mauro², Buy Rodrigo Andrés³,
Buy Rubén Exequiel⁴

¹ Director at Oftalmo Abad, Clínica de Ojos, Río Gallegos, Santa Cruz, Patagonia Argentina
^{2,3,4} Resident of Ophthalmology, Oftalmo Abad, Clínica de Ojos, Río Gallegos, Santa Cruz, Patagonia Argentina.

***Corresponding Author:** Prof. Dr. Luis E. Abad, Director at Oftalmo Abad, Clínica de Ojos, Río Gallegos, Santa Cruz, Patagonia Argentina.

ABSTRACT

Case report: describes the case of a patient with Diffuse Unilateral Subacute Neuroretinitis caused by a nematode, *The Ancylostoma Brasiliense*. The diagnosis is performed in the parasitology laboratory and the ophthalmoscopic examination is conducted by the indirect binocular ophthalmoscope. Supplementary examinations are conducted as well, such as retinography, campimetry, Ishihara Test (colour vision), and multifocal electroretinogram.

The treatment was immediately administered with the combination of oral anthelmintics together with the application of green argon laser directly on the worm with a single shot (spot: 200 μ , time: 150mseg and power: 160mW), and within 24 hours of laser treatment, daily for seven days was administered oral steroid.

Discussion: DUSN usually occurs in young people and children, most frequently affecting one eye. Its main differential diagnosis is with the multifocal choroiditis among others. The diagnosis will be made only once the larva is located in the subretinal space. The treatment was carried out at the first stage with the combination of oral anthelmintics with application of green argon laser and finally oral steroids.

Keywords: DUSN, *Baylisascaris*, *Ancylostoma*, *Onchocerca*, *Loa Loa*, *Wuchereria*, *Alaria*.

INTRODUCTION

In 1978, Gass (USA), described a syndrome characterized by being unilateral and affect young patients, initially called "Unilateral Wipe Out Syndrome." Subsequently, the name Diffuse Unilateral Subacute Neuroretinitis "DUSN" was adopted¹. In 1992, Souza (Brazil), described the first confirmed case of DUSN^{2,3}, with identification of the larvae in the sub-retinal space, in 1999, this same author described the first bilateral case of this disease. This infection is more common in the northeastern states of Brazil.

This infection affects mainly children and young adults and is not accompanied by extraocular clinical manifestations. In the initial phase, there is a decreased visual acuity, inflammation of the vitreous, papillitis, retinal vasculitis and greyish white retinal lesions. At the late stage, the ophthalmoscopic examination is presented with optic atrophy and diffuses alterations in the retinal pigment epithelium. Approximately 50%

of patients show in the affected eye, a visual acuity less or equal to 1/10.

The pathogenesis of DUSN is definitely related to the presence of larvae in the subretinal space that can be a nematode or trematode which cause local inflammatory changes probably due to toxic effects or immunologic stimulation from excretory products of the larvae^{4,5}. The larvae are characterized by their brightness, mobility and white coloration, with a variable size from 350 to 2000 microns its length was 20 times smaller. It was observed in some cases, an increase in the mobility of the worm with illumination.

It is believed that this infectious disease is part of a syndrome of multiple etiologies, caused by several species, depending on their location in the eye. Among the most commonly causing parasites are the *Toxocara canis* in Brazil and *Baylisascaris Procyonis* in northeastern United States. Less common are the *Ancylostoma Caninum*, *Ancylostoma Brasiliense*, *Onchocerca Volvulus*, *Loa Loa*, *Wuchereria Brancofti* and

Diagnosis and Treatment of 'Dusn' Diffuse Unilateral Subacute Neuroretinitis

Mesocercaria Alaria, which are also possible agents but not as frequent and aggressive as Baylisascaris Procyonis.

The diagnosis is confirmed by the identification of the larvae in the subretinal space. The electroretinogram (ERG) in DUSN can be particularly useful. The "b" wave is usually more affected than "a" wave with a ratio $b/a < 1$. As for the treatment of DUSN, direct photocoagulation of the larva can be made in the initial stages of the disease, preventing its progression to provide partial recovery of visual acuity. As for medical treatment, Thiabendazole, Diethylcarbamazine and Ivermectin are mainly administered, but they are not effective in all cases which reach a point of requiring surgical treatment.

CASE REPORT

A male patient, 27 years old, is treated in our clinic, coming from province of Misiones, more specifically from Puerto Iguazú (north-east of Argentina), presented with a unilateral loss in visual acuity, with a 20 days development period. In the case history, we found that he lived in his country house with wild animals.

In the Ophthalmological examination, there was a visual acuity of 2/10 in the right eye which did not improve with pinhole (stenopeic) glasses, and 8/10 in the left eye. In the biomicroscopic examination there were no signs of importance in either eye, strain was 17 mmHg. in the right eye and 19 mmHg. in the left eye. By the Indirect Binocular Ophthalmoscope, the right eye showed few inflammatory cells in the anterior vitreous body, found earlier, and the inferior macular area of the subretinal space showed a white worm, producing an intense glow with movement and surrounded by a diffuse area of yellowish color (Figure 1). The left eye was normal.

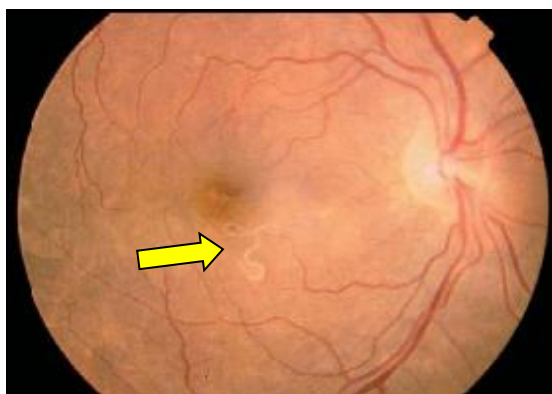


Figure1: Fundus exam of the right eye, revealed an image of yellowish white wrapping (arrow), caused by the nematode, located in the inferior macular area of the subretinal space.

Campimetry showed no significant changes in either eye with no evidence of colour vision (Ishihara Test). Multifocal electroretinography (mfERG) was then applied in the same eye, showing changes at the level of the macula (figure 2).

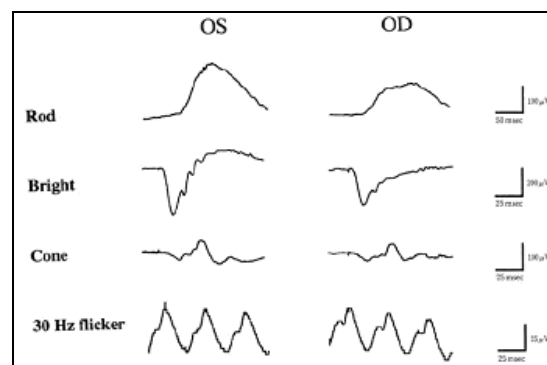


Figure2: Electroretinogram with more obvious alteration of the wave b in the right eye.

A combination of Anthelmintics, Albendazole 400mg and Diethylcarbamazine 100mg was immediately administered, together with the application of argon laser directly on the worm, by a single shot (spot: 200µ, time: 150msec and power: 160mW). Diethylcarbamazine was then continued to be administered for 21 days.

The next day, in the ophthalmoscopic follow up, we found the dead worm (opaque with no movements), with circular neuroretinitis temporal to the optic nerve. (Figure 3).

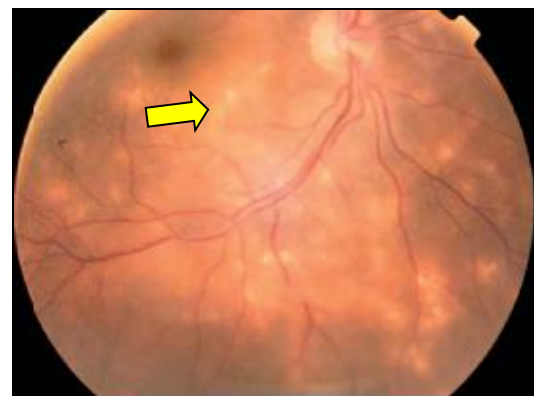


Figure3: Fundus exam after 24 hours of laser therapy, the nematode had no mobility or brightness. We can see in this picture a neuroretinitis with multiple evanescent white dots (arrow).

The patient was administered 40mg Dexamethasone orally, within 24 hours of laser treatment, daily for seven days. After one month, the vision of his right eye had improved to 6/10. In the indirect binocular ophthalmoscope, no activity or inflammation was observed at the site where the worm was hosted, also there was no diffuse pigmented changes in the inferior macular area of subretinal space. (Figure 4).

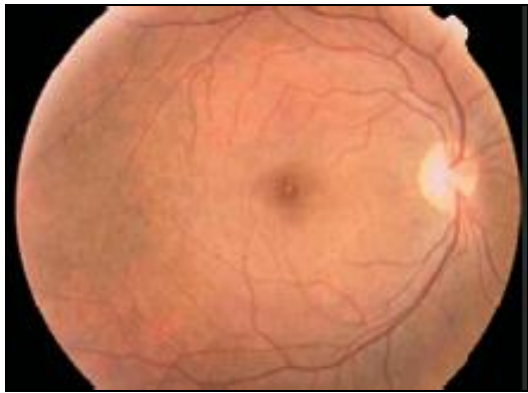

Figure4: Retinographic image, obtained a month of treatment, with the resolution of the infection.

DISCUSSION

The DUSN is clinically presented affecting only one eye with a higher predisposition in children, young adults and healthy individuals, without preference for race or sex.

In its early stages, the differential diagnosis of DUSN includes diseases that cause focal or multifocal chorioretinitis, such as multifocal choroiditis, Toxoplasmosis, Cytomegalovirus retinitis, acute multifocal placoid pigment epitheliopathy, Behçet disease, multiple evanescent white dot syndrome and Pseudo-presumed Ocular Histoplasmosis syndrome. In its later stages, the differential diagnosis includes conditions that cause optic atrophy, arteriolar attenuation and diffuse pigmentary abnormalities, such as histoplasmosis syndrome, post-traumatic chorioretinopathy, vascular occlusive disease, syphilitic chorioretinitis and unilateral retinitis pigmentosa.

The diagnosis was achieved mainly through the parasitological study and presumptive diagnosis through the indirect binocular ophthalmoscope .

According to the cases reported in Brazil, the larvae usually vary between 400 and 700 microns in length, except one case (first case of South America), which described a larva that measured between 1,500 and 2,000 microns in length. Until then, larvae of such size, had only been described in the northwest of the United States and Germany. Sometimes it is difficult to find the location of the larvae. It is believed that only 20 to 50% of cases of DUSN, the larva is detected with movement. Oliveira and Cols,

reported seven cases with clinical diagnosis without finding the larva.

Oréfica⁴ y Cols., reported 23 cases of DUSN, and in just two patients (11.5%), the larva was found in the sub-retinal space. Recently, this same author identified two patients with suspected disease bilaterally. In these two cases, only one of them was identified with larvae in one eye.

The clinical classification of the disease is complex, variations can occur between different examiners and even in the observation of a single examiner at different times. In this study we used subjectively classification according to the degree of ocular alteration, from mild to severe. In the studies described above in Brazil, it was observed that the majority of cases were presented in advanced stages. In 80% of patients, visual acuity was corrected for less than 2/10, and more than half of the cases had pale optic disc, retinal vascular narrowing and atrophy of the retinal pigmented epithelium; these were classified as severe cases. The advanced degree of ocular abnormalities of these cases, was due to the failure to identify the larva in the sub-retinal space. The progression of the disease was prevented through a treatment with laser (photocoagulation), which also caused serious functional and ophthalmoscopic consequences.

REFERENCES

- [1] Gass JD, Gilbert WR Jr., Guerry RK, Scelfo R. Diffuse unilateral subacute neuroretinitis. *Ophthalmology* 1978;85:521-545.
- [2] Souza EC, Cunha SL. Neuroretinite subaguda unilateral difusa no Brasil: encontro da larva sub-retiniana. *Arq Bras Oftal* 1992;55:251-254.
- [3] Souza EC, Abujamra S, Nakashima Y, Gass JD. Diffuse bilateral subacute neuroretinitis: first patient with documented nematodes in both eyes. *Arch Ophthalmol* 1999;117:1349-1351.
- [4] Orefice F, Targino A, Coscarelli G, Ferro Cardoso MJ, Lemos S. DBSN Neuroretinite subaguda bilateral difusa: 2 casos clínicos. *Rev Bras Oftal* 2000;59:360-368.
- [5] McDonald HR, Kazacos KR, Schatz H, Johnson RN. Two cases of intraocular infection with *Alaria Mesocercaria* (Trematoda). *Am J Ophthalmol* 1994;117:447-455.

Citation: Prof. Dr. Luis E. Abad, et.al., *Diagnosis and Treatment of 'Dusn' Diffuse Unilateral Subacute Neuroretinitis. International Journal of Research Studies in Medical and Health Sciences. 2018; 3(4):14-16..*

Copyright: © 2018 Prof. Dr. Luis E. Abad , et.al. This is an open-access article distributed under the terms of the Creative Commons Attribution License, which permits unrestricted use, distribution, and reproduction in any medium, provided the original author and source are credited.